Respiratory-system Test bank

Physiology (9 lectures), anatomy (6 lectures), Microbiology (6 lectures)

Embryology (2 lectures) histology (2 lectures) Pathology (4 lectures)

Sources of questions: Past papers, Book questions, USMLE step 1 style questions.

Done by Ahmad T qatawneh.

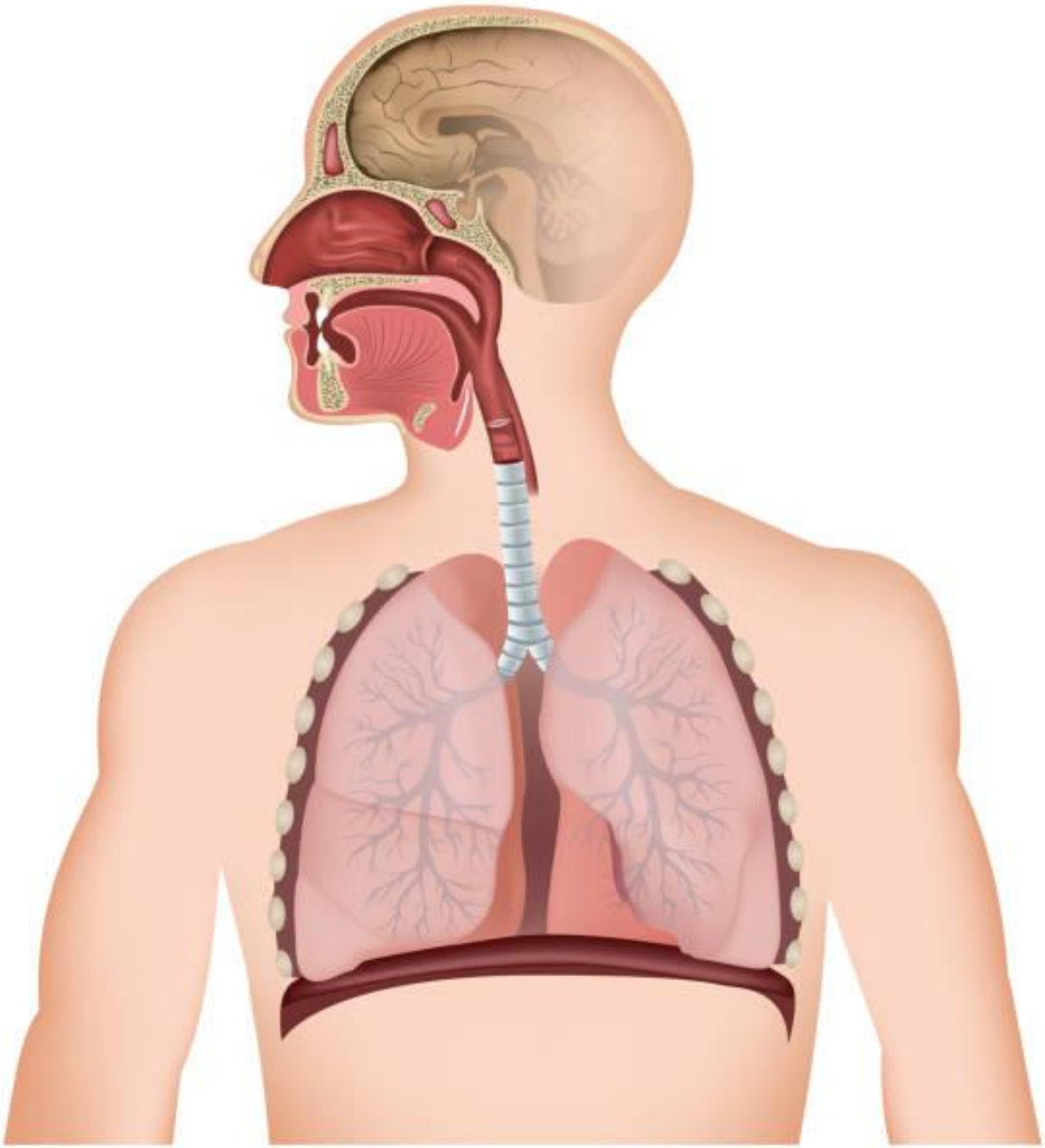

Physiology-past papers

1. All the following laboratory values are consistent with pulmonary fibrosis EXCEPT?

a. Increased residual volume
b. Increased vascular resistance
c. Normal or above normal FEV1/FVC
d. Decreased lung compliance
e. Normal or above normal peak expiratory flow (corrected for lung volume)

Answer: A

2. Which of the following is NOT true at FRC?

a. It is about 75% TLC.
b. The elastic recoil of the chest wall is outward.
c. The elastic recoil of the lung is inward.
d. The lung-thorax system is at rest.
e. pulmonary vascular resistance is the lowest

Answer: B

3. Regarding dead space, choose the FALSE statement

a. is defined as the volume of gas which does not take part in gas exchange
b. physiological dead space is the same as alveolar dead space
c. physiological dead space is measured by measuring mixed expiratory PCO2
d. mechanical ventilation (respirator) increases dead space volume.
e. increases whenever V/Q ratio is increased

Answer: C

4. Regarding pulmonary vascular resistance, which one of the following is true?

a. is low at high lung volumes
b. is low at low lung volumes
c. if increased, can cause right heart failure
d. is measured through routine pulmonary function tests
e. is more than systemic vascular resistance.

Answer: B

5. Which of the following is NOT true concerning respiratory distress syndrome inpremature infants?
a. Their ability to synthesize surfactant is limited.
b. Higher pressures are required to ventilate the lungs.
c. Lung compliance is low.
d. Positive pressure respirators are often used to assist them in breathing.
e. Alveoli tend to overexpand and sometimes burst at the end of inspiration

Answer: E

6. Which of the following structures contains blood with the highest PCO2?
a. Carotid bodies.
b. Pulmonary veins
c. Superior vena cava
d. The midportion of pulmonary capillaries.
e. Systemic arterioles

Answer: C

7. What is expected in a premature baby with IRDS? T=alveolar surface tension, C=lung compliance, Pa02=arterial PO2?
a. T: Increase, C: increase, Pa02: increase
b. T: Increase, C: decrease, PaO2: decrease
c. T: Decrease, C: decrease, Pa02: equal
d. T: Increase, C: increase, PaO2: decrease
e. T: Increase, C: increase, PaO2: decrease

Answer: B

8. In an asthmatic attack,which of the following is expected ?
a. Wheezing sounds are heard during inspiration more than that during expiration.
b. Bronchodilators are contraindicated.
c. Work of breathing is increased.
d. FEV1 is expected to increase.
e. Every asthmatic patients is a member of the COPD family.

Answer: C

9. In the presence of active surfactants, all of the following are expected to decrease EXCEPT?
a. Tendency of the lung to collapse
b. Lung compliance
c. Surface tension forces in the alveoli
d. Lymph flow in the lung
e. Work of breathing.

Answer: B

10. Compared to a normal individual, a patient with idiopathic pulmonary fibrosis , one of the following is expected to be more than normal ?

a. TLC
b. Total pulmonary vascular resistance
c. FEV1
d. PaO2
e. Resting volume of lung-thorax system

Answer: B

11. Following a stab wound in the chest wall, the lung will ….. and the chest wall will …. ?

a- Expand, expand
b- Both become fixed at the FRC
c- Collapse, Collapse
d- Expand, Collapse
e- Collapse, Expand

Answer: E

12. Using the following data, calculate the physiological dead space, Tidal volume=600 ml Alveolar ventilation = 4.3 L/min, PaCO2=40 mmHg, PECO2=28 mmHg:

a- 100 ml
b- 150 ml
c- 180 ml
d- 200 ml

Answer: C

13. which of the following regarding Residual volume is correct?

a- It is the volume that remains in the lung after tidal volume expiration.
b- It decreases with COPD.
c- It decreases with fibrosis.
d- It remains the same during the entire life of a human being.

Answer: D

14. Which of the following values is above normal in-patient suffering from severe respiratory muscle weakness?

a- Tidal volume
b- Oxyhemoglobin Saturation.
c- Vital capacity
d- Arterial PH
e- Arterial PCO2

Answer: E

15. A 12 years-old boy has a severe asthmatic attack with wheezing. His arterial pO2 is 60 mmHg and pcO2 is 30 mmHg. His:

a- FEV1/FVC % is increased.
b- V/Q ratio is increased in the affected areas of his lung
c- Arterial pCO2 is higher than normal because of inadequate gas exchange
d- arterial pCO2 is lower than normal because hypoxemia is causing him to hyper-ventilate
e- Residual volume is reduced

Answer: D

16. The largest cross-sectional area and therefore lower resistance of airways?

a- Trachea
b- Alveoli
c- Bronchioles
d- A+C

Answer: B

17. At the end of normal quite expiration, just before the start of inspiration, the lungs are said to be in:

a- RV
b- ERV
c- FRC
d- IRV
e- TLC

Answer: C

18. Oxygens percentage in the atmospheric air is …… that CO2 percentage and its solubility in solution (Example: Blood) is …… than CO2 solubility.

a- Lower, higher
b- Higher, lower
c- Lower, lower
d- Higher, higher

Answer: B

19. Which of the following is the most factor that can increase the volume of air entering the lung?

a- Increase in the pressure gradient.
b- Increase in action potential
c- Both a+b
d- Decrease in the pressure gradient

Answer: A

20. Fick's law depend on multiple factors, which one of them will have the most effect when observing the diffusion of different gases?
a- Partial pressure gradient
b- Temperature
c- Diffusion distance
d- Diffusion coefficient
e- Diffusion surface area
Answer: D

21. Which of the following will decrease diffusion?
a- Decreased surface area
b- Increased fluid in the lung
c- Decreased pressure coefficient
d- All the above
Answer: D

22. The primary force responsible for the movement of air into the lungs during inspiration?
a- Atm-pressure
b- Muscular spasm
c- Reduced surface tension of alveoli
d- Pressure difference between atmospheric-intrapulmonary.
e- Muscular relaxation
Answer: D

23. Even after forceful exhalation, a certain volume of air remains in the lungs, referred to as?
a- Tidal volume
b- ERV
c- Vital capacity.
d- Residual volume.
e- IRV
Answer: D

24. Regarding intrapleural pressure, which one is true?
a- Less than ATM-pressure only during inspiration
b- Becomes equal to external environmental air pressure by action of respiratory muscles
c- Difference between the pressure in the pleural cavity and that within the alveoli
d- Always less than ATM-pressure.
e- Increases in positivity when the diaphragm and external intercostal muscle contract
Answer: D

25. In a normal human, The total lung capacity (TLC) is approximately equal to?

a- 6 L
b- 2 L
c- 4 L
d- 9 L
e- 15 L
Answer: A

26. Vital capacity is defined as?
A- Sum of all lung volumes
B- Sum of tidal volume plus residual volume
C- Sum of inspiratory reserve volume plus expiratory reserve volume
D- Sum of Inspiratory reserve volume plus tidal volume and expiratory reserve volume
Answer: D

27. Which of the following will the have the highest percentage of CO2?
A- Alveolar air
B- Pulmonary arteries
C- Pulmonary veins
D- Interstitial fluid
E- Systemic arteries
Answer: B

28. At the end of quite respiration, muscles are relaxed and lungs content represents.
a- RV
b- ERV
c- FRC
d- IRV
e- TLC
Answer: C

29. Regarding surfactants, one is true?
a- Increase pleural pressure
b- Reduce surface tension of the fluid lining the alveoli
c- Decrease alveolar pressure
d- Make inspiration more difficult
e- Can cause pneumothorax
Answer: B

30. Assuming a normal anatomic dead space of 150 ml and a fixed respiratory minute ventilation of 6 L /min. Which combination of respiratory rate and tidal volume will give the largest alveolar ventilation?
a- 200 ml at 30 breaths/min
b- 300 ml at 20 breaths/min
c- 400 ml at 15 breaths/min

d- 600 ml at 10 breaths/min
e- Alveolar ventilation is not affected by tidal volume and respiratory rate
Answer: D

31. If dead space is one third of the tidal volume and arterial PCO2 is 45 mmHg,what is the mixed expired pCO2?
a- 20 mmHg
b- 30 mmHg
c- 40 mmHg
d- 45 mmHg
e- 60 mmHg
Answer: B

32. Which person would be expected to have the largest PAO2-PaO2 gradient? (Astand for alveolar and a-stands for arterial)
a- Normal person during exercise
b- Person with pulmonary fibrosis
c- Person with anemia but normal lungs
d- Person at 5000 meter above the sea level
Answer: B

33. A patient with restrictive lung disease will have a relatively normal?
a- FEV1
b- FVC
c- V/Q ratio
d- FEV1/FVC
e- Pulmonary vascular resistance
Answer: D

34. The greatest increase in the physiological dead space would be expected with?
a- Pulmonary embolism
b- Atelectasis's.
c- Pneumothorax
d- Bronchoconstriction.
e- Decrease V/Q ratio
Answer: A

35. Regarding physiological dead space, one of the following is wrong?
a- Generally, is equal to or greater than the anatomic dead space
b- Increased in lung disease
c- Increased whenever the V/Q ratio is increased
d- Equal to alveolar wasted volume (alveolar dead space)
Answer: D

36. Which of the following statements regarding surfactants is incorrect?
a- Responsible for hysteresis
b- Increases pulmonary resistance
c- Commonly deficient in term-neonates
d- Prevents the occurrence of pulmonary edema
e- Its production needs corticosteroids
Answer: C

37. Regarding lung compliance, all of the following are correct EXCEPT?
a- Expressed as unit change in volume per unit change in pressure.
b- Maximal during quite breathing
c- The more surface tension, the more the compliance
d- Decreases in fibrosis
e- Increases in emphysema
Answer: C

38. One of the following is true regarding FRC?
a- It is resting volume of the lung
b- It is resting volume of the thorax
c- At FRC, intra-alveolar pressure= atmospheric pressure
d- At FRC, intra-pleural pressure is more than atmospheric pressure
e- At FRC, lung compliance is the lowest
Answer: C

39. A person breathes into and from a spirometer (volume 12 liters) containing 10% helium gas mixture. After equilibration, helium concentration of expired gas was found to be 6.67%. His ERV is 4.2 liters. What is his residual volume? (Hint: V1C1=V2C2)
a- 1000 ml
b- 1200 ml
c- 1800 ml
d- 1500 ml
Answer: C

40. The work of breathing is:
a- Inversely related to lung compliance
b- Remains constant during exercise
c- Not affected by airway resistance
d- Is less in pulmonary fibrosis
e- Is less in emphysema
Answer: A

41. Regarding Pneumothorax, one of the following isn't true?
a- Diameter of the thorax increases
b- Venous return decreases
c- Vital capacity (VC) decreases
d- Lung compliance increases
e- Lung collapses
Answer: D

42. Which of the following is not correct regarding exhalation (expiration)?
a- Expiration is typically a passive process
b- Expiration can be active
c- The elastic properties of the lung tissue help it to excel deoxygenated air outside during exhalation
d- In COPD, patients face problems mainly during expiration.
e- Exhalation starts when the expiratory muscles relax.
Answer: E

43. All of the following lab-values are consistent with Pulmonary fibrosis except?
a- Normal or above FEV1/FVC ratio
b- Increased vascular resistance
c- Normal or above normal peak expiratory flow (corrected for lung volume)
d- Increased residual volume (RV)
e- Decreased compliance
Answer: D

44. In normal individual, regarding gas exchange across pulmonary capillaries during mild exercise, which of the following statements is TRUE?
a- CO2 crosses the membrane easier than 02
b- Diffusing capacity of the lung for 02 is more than for CO2, the most important factor to play role is the molecular weight of both gases
c- The length of capillary required for gas equilibrium is shorter during exercise
d- ABGs become grossly abnormal
e- Equilibrium across the respiratory membrane is never achieved
Answer: A

45. One of the followings is expected in idiopathic pulmonary fibrosis.
a- lower than normal FRC.
b- higher than normal tidal volume.
c- lower than normal pulmonary vascular resistance.
d- higher than normal TLC.
e- higher than normal lung compliance
Answer: A

46. Regarding bronchial asthma, all the following statements are true EXCEPT?
a- Cough suppressants are highly indicated
b- Airway resistance is increased.
c- During the attack, FEV1.0/FVC is < 80%
d- Bronchodilators can be given to asthmatic patients
e- Patients might be allergic to pollens
Answer: C

47. Regarding lung diseases, one of the following is true?
a- Increase in the diameter of the airways by 10% results in a increase in airwayresistance by more than 10%
b- COPDS are least common seen in clinical Practice
c- Pulmonary fibrosis is an example of increase airway resistance.
d- In pulmonary fibrosis, FEF1/FVC ratio is greater or equivalent to normal
e- In obstructive lung diseases, difficulty is during inhaling rather than during exhaling
Answer: D

48. One of the following PFT values are consistent with both obstructive and restrictive lung diseases?
a- Decreased residual volume
b- Normal or above normal TLC
c- Decreased vascular resistance
d- Decreased FEV1.0
e- Decreased FEV1.0/FVC
Answer: D

49. Which of the following is FALSE concerning airway resistance (R)?
a- In the later generations, the radii are smaller, increasing the total resistance at each successive generation.
b- Under normal conditions, R resides mainly in the large airways
c- Whenever R is increased FEV1.0/FVC is below normal.
d- Airway resistance can be increased by loss of tissue elasticity and contraction of bronchial smooth muscles
Answer: A

50. When the inspiratory muscles are relaxed, the lungs are said to be at ?
a- Vital capacity
b- Residual volume
c- Minimal volume
d- Functional residual capacity
e- Inspiratory capacity
Answer: D

51. Which of the following statements regarding the figure is true?

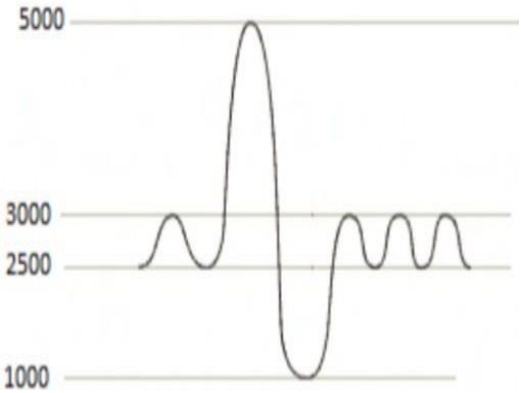

a- VC cannot be calculated
b- This person has very large physiological dead space.
c- This person has fibrosis
d- This person has COPD
e- This person could be normal

Answer: E

52. Place the following steps for normal inhalation in order:

(1) decrease in intrapleural pressure to 754 mmHg (from -4 mmHg to -6 mmHg).
(2) flow of air from higher to lower pressure (inhalation).
(3) lung size increases.
(4) decrease in intra-alveolar pressure to 759 mmHg (-1 mmHg).
(5). contraction of the diaphragm + external intercostals muscles

a- 5, 2, 3 ,4 ,1
b- 1, 3 ,4 ,5 ,2
c- 5 ,4 ,3 ,2 ,1
d- 5, 1 ,3 ,4 ,2
e- 1, 2, 3, 4 ,5

Answer: D

53. Lack of O2 equilibration is due to: **Diffusion limitation**

54. Patient with inadequate surfactant (RDS) will have relatively normal: **FEV1/FVC**

55. What would be the expected effect of pulmonary edema on pulmonary diffusion capacity for O2? **Reduce diffusion capacity for O2 & CO2**

56. Regarding residual volume represents the following except: r**esting volume in the lung (it's the minimal volume which represents the resting volume)**.

57. The O2 consumption of the respiratory muscle is decreased by: **A decrease in airway resistance**

58. Person suffers from stab injury and air entered, when pneumothorax? collapse of the lung -> venous return will decrease significantly -> **the person will die from decreased VR before dying from the collapse.**

59. Which parameter decrease with emphysema? **Diffusion area**

60. Intrapleural pressure: **Always less than alveolar pressure**

61. Tidal volume = 550 ml Pulmonary capacity = 6000 ml Dead space = 150 ml Ventilation rate 14ml/min Resting alveolar ventilation is? Ans: 5.6 L/min

62. Which of the following does not play a role in inspiration: **Relaxation of diaphragmatic muscle.**

63. With tidal volume of 450ml and arterial PCO2 of 40mmHg and mean expired and PCO2 of 32 and respiratory rate of 20/min, alveolar ventilation would be**: 7.2l/min**
64. Surfactants prevent lung collapse by: **Decreasing the pressure within alveoli**
65. Wrong about COPD: **decreased compliance**
66. Wrong about physiological dead space: **decreased in pulmonary embolism**
67. Wrong about restrictive diseases: **FEV1.0 is unchanged**
68. True regarding pneumothorax: **lung collapsed inwards and chest springs outwards**
69. True about the end of forced expiration: **lung tending to collapse, chest expand, lung-chest expand**
70. Lowest PCO2 is found in: **first portion of expired air**
71. True in case of fibrosis: **decreased RV, VC & TLC.**
72. which of the following test can be used to detect diffusion capacity abnormalities of the lung: **diffusion capacity of CO**
73. if at rest alveolar pressure was 0 and IPP was -4 mmHg, which of the following represent pressures at the end of inspiration with an open epiglottis: **alveolar pressureis 0 and IPP is: -6 mmHg.**
74. which of the following decrease during emphysema: **surface area of perfusion**
75. True regarding a patient with pulmonary fibrosis: **Decreased peak expiratory flow, decreased FEV1 and increase collapsing forces**
76. True regarding the diffusion capacity (DL) for oxygen: **Is indirectly measured through CO.**
77. One is considered a wrong statement: CO2 dissolved is less than O2 dissolved.
78. RR=10 breaths/minute, tidal volume=600mL, Vd=150mL, then respiratory minute ventilation (RMV) and alveolar ventilation (AV) respectively: **6L/minute, 4.5L/minute**
79. the base of the lungs receives more inspired air due to the fact: **base is more compliant**
80. Wrong regarding an individual with pulmonary edema, which is wrong: oxygen transport becomes "perfusion" limited.
81. Which of the following should be avoided with emphysema patient: **pure O2 supplementation**

Explanation: treating a chronic emphysema patient with oxygen **increased the blood oxygen levels too rapidly**. This may result in knocking out his hypoxic drive resulting in apnea, hypercapnia and causing further depression of the respiratory drive leading to respiratory failure.

Physiology-Selected Book questions (Guyton, BRS)

1- The pleural pressure of a normal 56-year-old woman is approximately −5 cm H2O during resting conditions immediately before inspiration (i.e., at functional residual capacity [FRC]). What is the pleural pressure (in cm H2O) during inspiration?
a- +1

b- +4
c- 0
d- −3
e- -7

Answer: e

2- The above figure shows three different curves (S, T, and U) for isolated lungs subjected to various transpulmonary pressures. Which of the following best describes the relative compliances for the three curves?

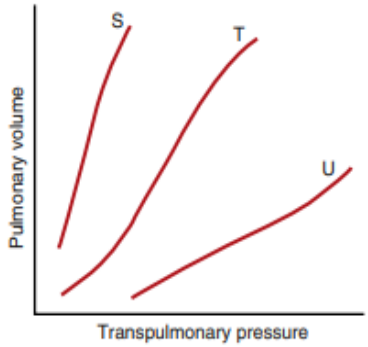

a- S < T < U
b- S < T > U
c- S − T − U
d- S > T < U
e- S > T > U

Answer: e

3- A 22-year-old woman inhales as much air as possible and exhales as much air as she can, producing the spirogram shown in the figure. A residual volume of 1.0 liter was determined using the helium dilution technique. What is her FRC (in liters)?

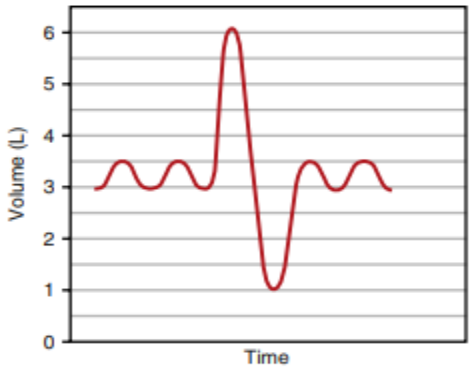

a- 2.0
b- 2.5
c- 3.0
d- 3.5
e- 4.0
f- 5.0

Answer: a

4- The various lung volumes and capacities include the total lung capacity (TLC), vital capacity (VC), inspiratory capacity (IC), tidal volume (VT), expiratory capacity (EC), expiratory reserve volume (ERV), inspiratory reserve volume (IRV), functional residual capacity (FRC), and residual volume (RV). Which of the following lung volumes and capacities can be measured using direct spirometry without additional methods?

	TLC	VC	IC	VT	EC	ERV	IRV	FRC	RV
A)	No	No	Yes	No	Yes	No	Yes	No	No
B)	No	Yes	Yes	Yes	Yes	Yes	Yes	No	No
C)	No	Yes	Yes	Yes	Yes	Yes	Yes	Yes	No
D)	Yes	Yes	Yes	Yes	Yes	Yes	Yes	No	Yes
E)	Yes	Yes	Yes	Yes	Yes	Yes	Yes	Yes	Yes

Answer: B

5- With a slow decrease in left heart function, which of the following will minimize the formation of pulmonary edema?

a- An increase in plasma protein concentration due to fluid loss
b- Increase in the negative interstitial hydrostatic pressure
c- Increased pumping of lymphatics

d- Increase in the concentration of interstitial protein

Answer: C

6- A patient has a dead space of 150 milliliters, FRC of 3 liters, VT of 650 milliliters, ERV of 1.5 liters, TLC of 8 liters, and respiratory rate of 15 breaths/min. What is the alveolar ventilation (Va)?

a- 5 L/min
b- 7.5 L/min
c- 6.0 L/min
d- 9.0 L/min

Answer: B

7- A healthy 10-year-old boy Mohammad Emyan breathes quietly under resting conditions. His tidal volume is 400 milliliters and his ventilation frequency is 12/min. Which of the following best describes the ventilation of the upper, middle, and lower lung zones in this boy?

dle, and lower lung zones in this boy?

	Upper Zone	Middle Zone	Lower Zone
A)	Highest	Lowest	Intermediate
B)	Highest	Intermediate	Lowest
C)	Intermediate	Lowest	Highest
D)	Lowest	Intermediate	Highest
E)	Same	Same	Same

Answer: D

8- An experiment is conducted in two persons (subjects T and V) with identical VTs (1000 milliliters), dead space volumes (200 milliliters), and ventilation frequencies (20 breaths per minute). Subject T doubles his VT and reduces his ventilation frequency by 50%. Subject V doubles his ventilation frequency and reduces his VT by 50%. What best describes the total ventilation (also called minute ventilation) and Va of subjects T and V?

	Total Ventilation	VA
A)	T < V	T = V
B)	T < V	T > V
C)	T = V	T < V
D)	T = V	T = V
E)	T = V	T > V
F)	T > V	T < V
G)	T > V	T = V

Answer: E

9- If alveolar surface area is decreased 50% and pulmonary edema leads to a doubling of diffusion distance, how does diffusion of O2 compare with normal?

a- 25% increase
b- 50% increase
c- 25% decrease
d- 50% decrease
e- 75% decrease

Answer: E

10-Which of the following sets of differences best describes the hemodynamics of the pulmonary circulation when compared with the system circulation?

	Flow	Resistance	Arterial Pressure
A)	Higher	Higher	Higher
B)	Higher	Lower	Lower
C)	Lower	Higher	Lower
D)	Lower	Lower	Lower
E)	Same	Higher	Lower
F)	Same	Lower	Lower

Answer: F

11- Blood gas measurements are obtained in a resting patient who is breathing room air. The patient has an arterial content of 19 ml O2/min with a Po2 of 95. The mixed venous O2 content is 4 ml O2/100 ml blood. Which condition does the patient have?

a- An increase in physiological dead space
b- B Pulmonary edema
c- A low Hb concentration
d- A low cardiac output

Answer: D

12- A normal male subject has the following initial conditions (in the steady state), If you ignore the contribution of dissolved O2 to the O2 content, what is the venous O2 content?

a- 2.2 ml O2/100 ml blood
b- 3.2 ml O2/100 ml blood
c- 4 ml O2/100 ml blood
d- 4.6 ml O2/100 ml blood
e- 6.2 ml O2/100 ml blood
f- 10.8 ml O2/100 ml blood
g- 16 ml O2/100 ml blood

Answer: D

13- The forces governing the diffusion of a gas through a biological membrane include the pressure difference across the membrane (ΔP), the cross-sectional area of the membrane (A), the solubility of the gas (S), the distance of diffusion (d), and the molecular weight of the gas (MW). Which changes increase the diffusion of a gas through a biological membrane?

	ΔP	A	S	d	MW
A)	Increase	Increase	Increase	Increase	Increase
B)	Increase	Increase	Increase	Increase	Decrease
C)	Increase	Decrease	Increase	Decrease	Decrease
D)	Increase	Increase	Increase	Decrease	Increase
E)	Increase	Increase	Increase	Decrease	Decrease

Answer: E

14- Arterial Po2 is 100 mm Hg and arterial Pco2 is 40 mm Hg. Total blood flow to a muscle is 700 ml/min. There is a sympathetic activation resulting in a decrease in blood flow of this muscle to 350 ml/min. There is no neuromuscular activation, and thus no contraction of the muscle. Which of the following will occur?

	Venous Po_2	Venous Pco_2
A)	↑	↓
B)	↓	↑
C)	↓	↔
D)	↔	↑
E)	↑	↑
F)	↓	↓
G)	↔	↔

Answer: B

15- . A 45-year-old man at sea level has an inspired O2 tension of 149 mm Hg, nitrogen tension of 563 mm Hg, and water vapor pressure of 47 mm Hg. A small tumor pushes against a pulmonary blood vessel, completely blocking the blood flow to a small group of alveoli. What are the O2 and carbon dioxide (CO2) tensions of the alveoli that are not perfused (in mm Hg)?

Answer: B

	CO_2	O_2
A)	0	0
B)	0	149
C)	40	104
D)	47	149
E)	45	149

16- Which of the following best describes the effect of decreasing V/Q ratio on the alveolar Po2 and Pco2?

	CO_2 Tension	O_2 Tension
A)	Decrease	Decrease
B)	Decrease	Increase
C)	Decrease	No change
D)	Increase	Decrease
E)	Increase	Increase

Answer: D

17- A 23-year-old medical student has mixed venous O2 and CO2 tensions of 40 mm Hg and 45 mm Hg, respectively. A group of alveoli are not ventilated in this student because mucus blocks a local airway. What are the alveolar O2 and CO2 tensions distal to the mucus block (in mm Hg)?

Answer: C

	CO_2	O_2
A)	40	100
B)	40	40
C)	45	40
D)	50	50
E)	90	40

18- A 67-year-old man has a solid tumor that pushes against an airway, partially obstructing air flow to the distal alveoli. Which point on the V/Q line of the O2- CO2 diagram below corresponds to the alveolar gas of these distal alveoli?

Answer: B

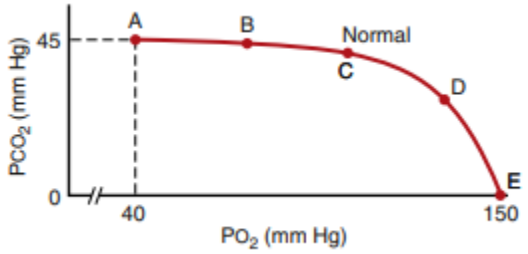

Explanation: When the ventilation is reduced to zero (Va/Q = 0), alveolar air equilibrates with the mixed venous blood entering the lung, which causes the gas composition of the alveolar air to become identical to that of the blood. This occurs at point A, where the alveolar Po2 is 40 mm Hg and the alveolar Pco2 is 45 mm Hg, as shown in the figure. A reduction in Va/Q (caused by the partially obstructed airway in this problem) causes the alveolar Po2 and Pco2 to approach the values achieved when Va/Q = 0.

19- Using the same previous figure, A 55-year-old man has a pulmonary embolism that completely blocks the blood flow to his right lung. Which point on the V/Q line of the O2-CO2 diagram above corresponds to the alveolar gas of his right lung?

Answer: E

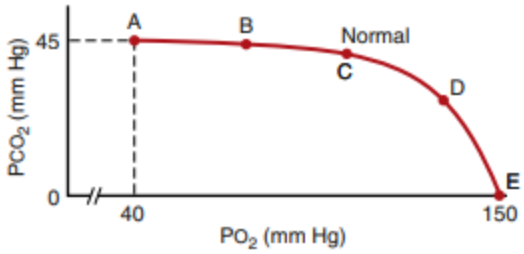

Explanation: An increase in Va/Q caused by the partially obstructed blood flow in this problem causes the alveolar Po2 and Pco2 to approach the values achieved when Va/Q = ∞. The point at which Va/Q is equal to infinity corresponds to point E in the figure (inspired gas).

20- The figure above shows a lung with a large shunt in which mixed venous blood bypasses the O2 exchange areas of the lung. Breathing room air produces the O2 partial pressures shown on the diagram. What is the O2 tension of the arterial blood (in mm Hg) when the person breathes 100% O2 and the inspired O2 tension is greater than 600 mm Hg?

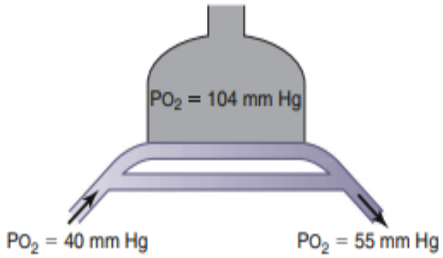

a- 40
b- 55
c- 60
d- 175
e- 200
f- 600

Answer: C

Explanation: Breathing 100% O2 has a limited effect on the arterial Po2 when the cause of arterial hypoxemia is a vascular shunt. However, breathing 100% O2 raises the arterial Po2 to more than 600 mm Hg in a normal subject. With a vascular shunt, the arterial Po2 is determined by (a) highly oxygenated end-capillary blood (Po2 > 600 mm Hg) that has passed through ventilated portions of the lung, and (b) shunted blood that has bypassed the ventilated portions of the lungs and thus has an O2 partial pressure equal to that of mixed venous blood (Po2 = 40 mm Hg). A mixture of the two bloods causes a large fall in Po2 because the O2 dissociation curve is so flat in its upper range.

21- An anesthetized man is breathing with no assistance. He then undergoes artificial ventilation for 10 minutes at his normal VT but at twice his normal frequency. He undergoes ventilation with a gas mixture of 60% O2 and 40% nitrogen. The artificial ventilation is stopped, and he fails to breathe for several minutes. This apneic episode is due to which of the following?

a- High arterial Po2 suppressing the activity of the peripheral chemoreceptors
b- Decrease in arterial pH suppressing the activity of the peripheral chemoreceptors
c- Low arterial Pco2 suppressing the activity of the medullary chemoreceptors
d- High arterial Pco2 suppressing the activity of the medullary chemoreceptors
e- Low arterial Pco2 suppressing the activity of the peripheral chemoreceptors

Answer: C

Explanation: This patient would have increased alveolar ventilation (Va) because of increase in the respiratory frequency, therefore resulting in a decrease in arterial Pco2. The effect of this decrease in Pco2 would be an inhibition of the chemo sensitive area and a decrease in ventilation until Pco2 was back to normal. Breathing high O2 does not decrease nerve activity sufficient to decrease respiration. The response of peripheral chemoreceptors to CO2 and pH is mild and does not play a major role in the control of respiration.

End of physiology questions.

Microbiology past-papers

1- Which of the following toxins can cause scarlet fever?

a- DNAse
b- Streptolysin S
c- Hyalinase.
d- C5a protease
e- Erythrogenic toxin

Answer: E

2- Which of the following statements concerning antigenic drift in influenza viruses is Correct?

a- It results in major antigenic change
b- It is exhibited only by influenza A viruses
c- It is caused by frameshift mutations in viral genes
d- It results in new subtypes over time
e- It affects predominantly the matrix protein

Answer: D

3- Highly pathogenic H5N1 avian influenza HPAI can infect humans with a high mortality rate, but it has not yet resulted in pandemic. The following are characteristics of HPAI, except for one. Which one is not?

a- Efficient human-to-human transmission
b- Presence of avian influenza genes
c- Efficient infection of domestic poultry
d- Contains segmented RNA genome
e- Both high pathogenicity and low pathogenicity avian influenza viruses can cause disease in human beings

Answer: A

4- All the following are true about S. pyogenes except:

a- Can't be diagnosed by smear
b- Available vaccine against its capsule
c- Treated by penicillin with no resistance
d- The capsule is an important virulence factor

Answer: B

5- Which of the following sentences is wrong:

a- Antibiotics prevent glomerulonephritis and rheumatic fever .
b- Strep. pyogenes is Bacitracin sensitive.
c- Untreated pharyngitis may results in otitis media.
d- People who are infected by GAS and develop later on AGN , will not develop this again if they're reinfected again by GAS .

Answer: A

6- Wrong about genetic reassortment:
- a- It is happened in Influenza A virus
- b- Leads to Antigenic drift.

Answer: A

7- All of the following are associated with Group A streptococci EXCEPT:
- a- Necrotizing fasciitis.
- b- Impetigo
- c- Neonatal sepsis.
- d- Erysipelas
- e- Cellulitis.

Answer: C

8- A patient with egg allergy and should not be given influenza vaccine, to protect them from Influenza A and B you can use:

Answer: Oseltamivir or zanamivir

9- A boy present to the ER with strawberry tongue, rash on the chest and fever, his mother noticed whitish exudate on his tonsils 3 days ago, the causative microorganism ??

- a- Strep. agalactiae
- b- Strep. pyogenes
- c- Strep. Bovis

Answer: B

10-In which stage of pertussis is the characteristic whooping sound made?

- a- convalescence
- b- catarrhal
- c- Paroxysmal
- d- Prodromal
- e- None of the above

Answer: C

11-A 3-year-old child develops Haemophilus influenzae meningitis. Therapy is begun with cefotaxime. Why is this third-generation cephalosporin used rather than ampicillin?

- a- About 80% of Haemophilus influenzae organisms have modified penicillin-binding proteins that confer resistance to ampicillin.
- b- The drug of choice, trimethoprim–sulfamethoxazole, cannot be used because the child is allergic to sulfonamides.
- c- It is easier to administer intravenous cefotaxime than intravenous ampicillin.
- d- There is concern that the child will rapidly develop a penicillin (ampicillin)allergy.
- e- About 20% of Haemophilus influenzae organisms have a plasmid that encodes or β-lactamase

Answer: E

12- Humans become infected with Legionella pneumophila by one of the following?

a- Kissing a person who is a legionella carrier
b- Breathing aerosols from environmental water sources
c- Receiving a mosquito bite
d- Consuming undercooked pork
e- All the above

Answer: B

13- A 13-valent capsular polysaccharide protein conjugate vaccine for pneumococcal infections is recommended for:

a- For children up to age 18 years and for selected adults
b- Only on exposure to a patient with disease caused by the organism
c- For all children ages 2–60 months plus selected older children and adults with immunocompromising conditions
d- For children ages 24–72 months
e- For all age groups older than age 2 months

Answer: C

14- Which of the following statements regarding interferon- release assays (IGRAs) is correct?

a- They are useful for evaluating immunocompromised patients for active Tuberculosis.

b- they detect antigens present in all Mycobacterium species.
c- They are not available yet for testing in the hospitals.
d- They are performed using molecular probes that detect organism DNA.
e- They are used as alternatives to the tuberculin skin test to evaluate for latent tuberculosis.

Answer: E

15- Mycoplasma pneumoniae is considered. All of the following are methods to confirm the clinical suspicion except?

a- PCR amplification of Mycoplasma pneumoniae DNA in sputum
b- Culture of sputum for Mycoplasma pneumoniae
c- Gram stain of sputum smear
d- Culture of a lung aspirate for Mycoplasma pneumoniae
e- Enzyme immunoassay test of acute and convalescent sera

Answer: C

16- Which of the following statements regarding the prevention and treatment of influenza is correct?

a- Booster doses of vaccine are not recommended.
b- Drugs that inhibit neuraminidase are active only against influenza A.
c- As with some other live vaccines, the attenuated influenza vaccine should not be given to pregnant women.
d- The influenza vaccine contains several serotypes of virus.
e- The virus strains in the influenza vaccine do not vary from year to year.

Answer: D

17- Which of the following symptoms is not typical of influenza?

a- Fever
b- Muscular aches
c- Malaise
d- Dry cough
e- Rash

Answer: E

18-Which of the following infectious agents is most likely to cause a pandemic?

a- Influenza A virus
b- Streptococcus pyogenes
c- Influenza B virus
d- Respiratory syncytial virus
e- Influenza C virus

Answer: A

19-Which of the following infectious agents is most likely to cause a pandemic?

a- Influenza A virus
b- Streptococcus pyogenes
c- Influenza B virus
d- Respiratory syncytial virus
e- Influenza C virus

Answer: A

20- A primary mechanism responsible for the pathogenesis of AGN?

a- A net increase in intracellular cyclic adenosine monophosphate
b- Action of M protein
c- Action of IgA1 protease
d- Action of enterotoxin A
e- Inactivation of elongation factor 2

Answer: B

21- An 18-month-old boy has been playing with a child who develops Haemophilus influenzae meningitis. The boy's parents consult his pediatrician, who says she is comfortable that the child will be fine because he has been fully immunized with the polyribitol ribose phosphate (PRP)–protein conjugate vaccine. For what reason is it necessary to immunize infants of 2 months to 2 years of age with polysaccharide– protein conjugate vaccines?

a- The conjugate protein is diphtheria toxoid, and the goal is for the infant to develop simultaneous immunity to diphtheria.
b- infants 2 months to 2 years of age do not immunologically respond to polysaccharide vaccines that are not conjugated to a protein.
c- The conjugate vaccine is designed for older children and adults as well as infants.
d- Maternal (transplacental) antibodies against Haemophilus influenzae are gone from the infant's circulation by 2 months of age.
e- None of the above

Answer: B

22- An 8-year-old boy, who recently arrived in the United States, develops a severe sore throat. On examination, a greyish exudate is seen over the tonsils and pharynx with oral membrane that bleeds profusely when touching it, he also has lymphadenopathy The cause of the boy's pharyngitis is most likely:

a- Gram negative aerobic non encapsulated bacteria
b- Gram positive anaerobic encapsulated bacteria
c- Gram negative anaerobic encapsulated bacteria
d- Gram positive aerobic non encapsulated bacteria

Answer: D

23- All of the following statements regarding acellular pertussis vaccines are correct except?

a- All formulations of the vaccine contain at least two antigens.
b- the acellular vaccine has replaced the whole cell vaccine in the childhood vaccine series.
c- All children should receive five doses of the vaccine before school entry.
d- The vaccine is approved only for young children and adolescents.
e- The vaccine is safer than and as immunogenic as whole cell vaccines.

Answer: D

24- The definition of extensively drug-resistant (XDR) tuberculosis includes?

a- Resistance to isoniazid
b- Resistance to a fluoroquinolone
c- Resistance to capreomycin, amikacin or kanamycin
d- Resistance to rifampin
e- All the above

Answer: E

25- A 13-year-old boy develops infection with Mycoplasma pneumoniae. What is the risk for infection in other members of his household?

a- None; it is sexually transmitted
b- 1–3%
c- 10–15%
d- 20–40%
e- 50–90%

Answer: E

26- A patient presents with paranasal swelling and bloody exudate from both his eyes and nares, and he is nearly comatose. Necrotic tissue in the nasal turbinate's show no septate hyphae consistent with Rhizopus, Mucor, or Absidia. What is the most likely compromising condition underlying this infection?

a- Chronic sinusitis
b- Ketoacidotic diabetes
c- Neutropenia
d- B-cell defects
e- AIDS

Answer: B

27- - a male patient presents with skin rash and red tongue, which describes the causative agent?

a- Gram +, α hemolytic, catalase -
b- Gram +, β hemolytic, catalase -
c- Gram -, β hemolytic, catalase +
d- Gram-, α hemolytic, catalase +
e- Gram +, γ hemolytic, catalase +

Answer: B

28- Mechanism of action of toxin for bacteria grown in Bordet-Gengou medium is?

a- ADP ribosylation of GTP binding protein
b- ADP ribosylation of Gi
c- inhibition of acetylcholine
d- inactivation of elongation factor 2

Answer: B

End of past papers questions

Microbiology- Books + USMLE step-1 style questions

1- A 3-month-old infant is brought to the pediatric emergency department in severe respiratory distress. The child appears dehydrated, and there is a prominent peripheral lymphocytosis. The chest radiograph reveals perihilar infiltrates. The child's grandmother, who watches the infant now that the mother has returned to work, has had a dry hacking cough for about 2 weeks. The most likely causative agent is:

a- Haemophilus influenzae type b
b- Bordetella pertussis
c- Streptococcus agalactiae
d- Chlamydia pneumoniae
e- Bordetella bronchiseptica

Answer: B

2- In Question 1, the factor responsible for the profound lymphocytosis is:

a- A hemagglutinin
b- A polysaccharide capsule
c- An A/B structured toxin
d- A heat-labile toxin
e- A neuraminidase

Answer: C

3- Which of the following is not a recognized virulence factor of Bordetella pertussis?

a- Heat-labile toxin
b- Filamentous hemagglutinin
c- Tracheal cytotoxin
d- Pertussis toxin
e- Dermonecrotic toxin

Answer: A

4- A 65-year-old man comes to the emergency department feeling feverish and "really tired." He has a chronic cigarette cough, but this has dramatically increased in the past week and he has been producing whitish sputum. The previous day he had a temperature of 38°C and watery diarrhea. Physical examination reveals inspiratory and expiratory wheezes and rales over the right lower lung field. Chest radiography shows a patchy right lower lobe infiltrate. The differential diagnosis of this patient's disease is:

a- Streptococcus pneumoniae pneumonia
b- Legionella pneumophila pneumonia
c- Haemophilus influenzae pneumonia
d- Mycoplasma pneumoniae pneumonia
e- All of the above

Answer: E

5- All of the statements below regarding infections with Legionella are correct except:
- a- Hospitals that care for patients at risk for Legionella infections should know if their potable water systems contain Legionella.
- b- Human-to-human transmission is the major mechanism of transmission of Legionella infection.
- c- Legionella species can be visualized with Gram stain if carbolfuchsin is used for the counter stain.
- d- The chest radiograph of a patient who has Legionella pneumonia is indistinguishable from that of patients with pneumonia caused by other pathogens.
- e- A macrolide or quinolone are the drugs of first choice for treatment of Legionella infections.

Answer: B

6- A 60-year-old man has a 5-month history of progressive weakness and a weight loss of 13 kg along with intermittent fever, chills, and a chronic cough productive of yellow sputum, occasionally streaked with blood. A sputum specimen is obtained, and numerous acid-fast bacteria are seen on the smear. Culture of the sputum is positive for M tuberculosis. Which treatment regimen is most appropriate for initial therapy?
- a- Isoniazid and rifampin
- b- Sulfamethoxazole–trimethoprim and streptomycin
- c- Isoniazid, rifampin, pyrazinamide, and ethambutol
- d- Isoniazid, cycloserine, and ciprofloxacin
- e- Rifampin and streptomycin

Answer: C

7- A 47-year-old woman presents with a 3-month history of progressive cough, weight loss, and fever. Chest radiography shows bilateral cavitary disease suggestive of tuberculosis. Sputum culture grows an acid-fast bacillus that is a photochromogen (makes an orange pigment when exposed to light). The organism most likely is:
- a- Mycobacterium tuberculosis
- b- Mycobacterium kansasii
- c- Mycobacterium gordonae
- d- Mycobacterium avium complex
- e- Mycobacterium fortuitum

Answer: B

8- . A 31-year-old Asian woman is admitted to the hospital with a 7-week history of increasing malaise, myalgia, nonproductive cough, and shortness of breath. She has daily fevers of 38–39°C and a recent 5-kg weight loss. She had a negative chest radiograph when she entered the United States 7 years ago. The patient's grandmother died of tuberculosis when the patient was an infant. A current chest radiograph is normal; results of other tests show a decreased hematocrit and liver function test abnormalities. Liver and bone marrow biopsies show granulomas with giant cells and acid-fast bacilli. She is probably infected with:
- a- Mycobacterium leprae
- b- Mycobacterium fortuitum

c- Mycobacterium ulcerans
d- Mycobacterium gordonae
e- Mycobacterium tuberculosis

Answer: E

9- It is very important that the patient in the previous question (8) also be evaluated for:

a- HIV/AIDS
b- Typhoid fever
c- Liver abscess
d- Lymphoma
e- Malaria

Answer: A

Remember: AIDS+TB: lethal combination.

10-Of concern regarding the patient in question 8 is that she could be infected with a Mycobacterium that is:

a- Susceptible only to isoniazid
b- Resistant to streptomycin
c- Resistant to clarithromycin
d- Susceptible only to ciprofloxacin
e- Resistant to isoniazid and rifampin

Answer: E

11- Which of the following statements about the purified protein derivative (PPD) and the tuberculin skin test is most correct?

a- It is strongly recommended that medical and other health science students have PPD skin tests every 5 years.
b- Persons immunized with BCG rarely, if ever, convert to positive PPD skin test results.
c- The intradermal skin test is usually read 4 hours after being applied.
d- A positive tuberculin test result indicates that an individual has been infected with M tuberculosis in the past and may continue to carry viable mycobacteria.
e- A positive PPD skin test result implies that a person is immune to active tuberculosis.

Answer: D

12- All of the following organisms are rapidly growing mycobacteria except:

a- Mycobacterium fortuitum
b- Mycobacterium abscessus
c- Mycobacterium nonchromogenicum
d- Mycobacterium chelonae

Answer: C

13- A 72-year-old woman has an artificial hip joint placed because of degenerative joint disease. One week after the procedure, she has fever and joint pain. The hip is aspirated, and the fluid is submitted for routine culture and for culture for acid-fast https://kat.cr/user/Blink99/ CHAPTER 23 Mycobacteria 321 organisms. After 2 days of incubation, there is no growth on any of the media. After 4 days, however, bacilli are seen growing on the sheep blood agar plate, and similar-appearing acid fast bacilli are growing on the culture for acid-fast bacteria. The patient is most likely infected with:

a- Mycobacterium tuberculosis
b- Mycobacterium chelonae
c- Mycobacterium leprae
d- Mycobacterium kansasii
e- Mycobacterium avium complex

Answer: B

Remember: Mycobacterium chelonae Causes skin, soft tissue and musculoskeletal infections.

14- A 10-year-old child has a primary pulmonary M tuberculosis infection. Which of the following features of tuberculosis is most correct?

a- In primary tuberculosis, an active exudative lesion develops and rapidly spreads to lymphatics and regional lymph nodes.
b- The exudative lesion of primary tuberculosis often heals slowly.
c- If tuberculosis develops years later, it is a result of another exposure to M tuberculosis.
d- In primary tuberculosis, all of the infecting M tuberculosis organisms are killed by the patient's immune response.
e- In primary tuberculosis, the immune system is primed, but the PPD skin test result remains negative until there is a second exposure to M tuberculosis.

Answer: A

15- An 18-year-old sexually active woman develops left lower quadrant pain and fever. On pelvic examination, she has tenderness in the left adnexa, and a mass suggestive of a uterine tube abscess is palpated. The patient is diagnosed with pelvic inflammatory disease. Which of the following bacteria is considered to be a common cause of pelvic inflammatory disease?

a- Bacillus cereus
b- Haemophilus influenzae
c- Neisseria subflava
d- Mycoplasma pneumoniae
e- Chlamydia trachomatis

Answer: E

16- Which of the following is important in the pathogenesis of mycoplasmal infections?

a- The peptidoglycan in the mycoplasmal cell wall
b- The presence of lacto-N-neotetraose with a terminal galactosamine as the host cell receptor
c- The structures and the interactive proteins that mediate adhesion to host cells
d- The absence of cilia on the surface of the host cells
e- Growth in an anatomic site where anaerobic organisms thrive

Answer: C

17- Which type of test is most readily used to obtain laboratory confirmation of Mycoplasma pneumoniae infection?

a- Culture in broth containing serum, glucose, and a penicillin (to inhibit other flora)
b- PCR
c- electron microscopy
d- EIA tests on acute and convalescent phase sera

Answer: D

18- A 25-year-old woman is referred to the sexually transmitted diseases clinic because of contact with a male partner with gonorrhea. The woman has had 15 male sex partners since becoming sexually active. The likelihood that she also has genital Mycoplasma hominis infection is:

a- 1%
b- 5%
c- 15%
d- 40%
e- 90%

Answer: E

19-Infection with Mycoplasma genitalium:

a- is not restricted to the genitourinary tract.
b- results in inflammation causing urethritis in males and cervicitis in females.
c- is best treated with a first-generation cephalosporin.
d- is associated only with nongonococcal urethritis in males.
e- is asymptomatic unless a co-infection with Clamydia trachomatis is present.

Answer: B

20- Three months ago, a 53-year-old woman had surgery and chemotherapy for breast cancer. Four weeks ago, she developed a cough occasionally productive of purulent sputum. About 2 weeks ago, she noted a slight but progressive weakness of her left arm and leg. On chest examination, rales were heard over the left upper back when the patient breathed deeply. Neurologic examination confirmed weakness of the left arm and leg. Chest radiography showed a left upper lobe infiltrate. Contrast enhanced computed tomography showed two lesions in the right hemisphere. Gram stain of a purulent sputum specimen showed branching gram-positive rods that were partially acid fast. Which of the following organisms is the cause of this patient's current illness?

a- Actinomyces israelii
b- Corynebacterium pseudodiphtheriticum
c- Aspergillus fumigatus
d- Nocardia farcinica
e- Erysipelothrix rhusiopathiae

Answer: D

21- An 8-year-old boy, who recently arrived in the United States, develops a severe sore throat. On examination, a grayish exudate (pseudomembrane) is seen over the tonsils and pharynx. The differential diagnosis of severe pharyngitis such as this includes group A streptococcal infection, Epstein-Barr virus (EBV) infection, Neisseria gonorrhoeae pharyngitis, and diphtheria. The cause of the boy's pharyngitis is most likely:

a- A gram-negative bacillus
b- A single-stranded positive-sense RNA virus
c- A catalase-positive, gram-positive coccus that grows in clusters
d- A club-shaped gram-positive bacillus
e- A double-stranded RNA virus

Answer: D

22- The primary mechanism in the pathogenesis of the boy's disease (Question 21) is:

a- A net increase in intracellular cyclic adenosine monophosphate
b- Action of pyrogenic exotoxin (a superantigen)
c- Inactivation of acetylcholine esterase
d- Action of enterotoxin A
e- Inactivation of elongation factor 2

Answer: E

23- Which of the following aerobic gram-positive bacilli is modified acid-fast positive?

a- Nocardia brasiliensis
b- Lactobacillus acidophilus
c- Erysipelothrix rhusiopathiae
d- Listeria monocytogenes

Answer: A

24- A 48-year-old alcoholic man is admitted to a hospital because of stupor. He is unkempt and homeless and lives in an encampment with other homeless people, who called the authorities when he could not be easily aroused. His temperature is 38.5°C, and his blood pressure 125/80 mm Hg. He moans when attempts are made to arouse him. He has positive Kernig and Brudzinski signs, suggesting meningeal irritation. Physical examination and chest radiography show evidence of left lower lobe lung consolidation. An endotracheal aspirate yields rust-colored sputum. Examination of a Gram-stained sputum smear shows numerous polymorphonuclear cells and numerous gram-positive lancet-shaped diplococci. On lumbar puncture, the cerebrospinal fluid is cloudy and has a white blood cell count of 570/μL with 95% polymorphonuclear cells; Gram stain shows numerous gram-positive diplococci. Based on this information, the likely diagnosis is:

a- Pneumonia and meningitis caused by Staphylococcus aureus
b- Pneumonia and meningitis caused by Streptococcus pyogenes
c- Pneumonia and meningitis caused by Streptococcus pneumoniae
d- Pneumonia and meningitis caused by Enterococcus faecalis
e- Pneumonia and meningitis caused by Neisseria meningitidis

Answer: C

25- The patient in question 24 is started on antibiotic therapy to cover many possible microorganisms. Subsequently, culture of sputum and cerebrospinal fluid yields gram-positive diplococci with a minimum inhibitory concentration to penicillin G of greater than 2 μg/mL. The drug of choice for this patient until further susceptibility testing can be done is:

a- Penicillin G
b- Nafcillin
c- Trimethoprim–sulfamethoxazole
d- Gentamicin
e- Vancomycin

Answer: E

26- This infection of the patient in question 24 might have been prevented by

a- Prophylactic intramuscular benzathine penicillin every 3 weeks
b- A 23-valent capsular polysaccharide vaccine
c- A vaccine against serogroups A, C, Y, and W135 capsular polysaccharide
d- A vaccine of polyribosylribitol capsular polysaccharide covalently linked to a protein
e- Oral penicillin twice daily

Answer: B

27- The pathogenesis of the organism causing the infection (question 24) includes which of the following?

a- Invasion of cells lining the alveoli and entry into the pulmonary venule circulation
b- Resistance to phagocytosis mediated by M proteins
c- Migration to mediastinal lymph nodes where hemorrhage occurs

d- Lysis of the phagocytic vacuole and release into the circulation
e- Inhibition of phagocytosis by a polysaccharide capsule

Answer: E

28- A 13-valent capsular polysaccharide protein conjugate vaccine for the pathogen in question (24) is recommended:

a- For children up to age 18 years and for selected adults
b- Only on exposure to a patient with disease caused by the organism
c- For all children ages 2–23 months plus selected older children and adults with immunocompromising conditions
d- For children ages 24–72 months
e- For all age groups older than age 2 months

Answer: C

29- An 8-year-old boy develops a severe sore throat. On examination, a grayish-white exudate is seen on the tonsils and pharynx. The differential diagnosis includes group A streptococcal infection, Epstein-Barr virus infection, severe adenovirus infection, and diphtheria. (Neisseria gonorrhoeae pharyngitis would also be included, but the patient has not been sexually abused.) The cause of the boy's pharyngitis is most likely:

a- A catalase-negative gram-positive coccus that grows in chains
b- A single-stranded positive-sense RNA virus
c- A catalase-positive gram-positive coccus that grows in clusters
d- A catalase-negative gram-positive bacillus
e- A double-stranded RNA virus 7.

Answer: A

30- A primary mechanism responsible for the pathogenesis of the boy's disease (question 29) is:

a- net increase in intracellular cyclic adenosine monophosphate
b- Action of M protein
c- Action of IgA1 protease
d- Action of enterotoxin A
e- Inactivation of elongation factor 2

Answer: B

31- All the following statements regarding the hyaluronic acid capsule of S pyogenes are correct except:

a- It is responsible for the mucoid appearance of the colonies in vitro.
b- It is antiphagocytic.
c- It binds to CD44 on human epithelial cells.
d- t is an important virulence factor.
e- A vaccine against the capsule is currently available.

Answer: E

32- An 8-year-old girl develops Sydenham's chorea ("St. Vitus dance") with rapid uncoordinated facial tics and involuntary purposeless movements of her extremities, strongly suggestive of acute rheumatic fever. She has no other major manifestations of rheumatic fever (carditis, arthritis, subcutaneous nodules, skin rash). The patient's throat culture is negative for Streptococcus pyogenes (group A streptococci). However, she, her brother, and her mother all had sore throats 2 months ago. A test that if positive would indicate recent S pyogenes infections:

a- Ant streptolysin S antibody titer
b- Polymerase chain reaction for antibodies against M protein
c- ASO antibody titer
d- Esculin hydrolysis
e- Anti-hyaluronic acid antibody titer

Answer: C

33- Important methods for classifying and speciating streptococci are:

a- Agglutination using antisera against the cell wall group specific substance
b- Biochemical testing
c- Hemolytic properties (α-, β-, nonhemolytic)
d- Capsular swelling (quellung) reaction
e- All of the above

Answer: E

34- Enterococci can be distinguished from nonenterococcal group D streptococci on the basis of which of the following characteristics?

a- γ-Hemolysis
b- Esculin hydrolysis
c- Growth in 6.5% NaCl
d- Growth in the presence of bile
e- Gram stain morphology

Answer: C

35- A 47-year-old man with poorly controlled diabetes mellitus developed a bloody nasal discharge, facial edema, and necrosis of his nasal septum. Culture of his cloudy nasal secretions yielded Rhizopus species. What is the most important implication of this finding?

a- No diagnostic value because this mold is an airborne contaminant.
b- Consider treatment for rhinocerebral mucormycosis (zygomycosis).
c- Strongly suggestive of ketoacidosis.
d- Strongly suggestive of HIV infection.
e- The patient has been exposed to indoor mold contamination.

Answer: B

36- Which statement regarding aspergillosis is correct?

a- Patients with allergic bronchopulmonary aspergillosis rarely have eosinophilia.
b- Patients receiving parenteral corticosteroids are not at risk for invasive aspergillosis.
c- The diagnosis of pulmonary aspergillosis is frequently established by culturing Aspergillus from the sputum and blood
d- The clinical manifestations of aspergillosis include local infections of the ear, cornea, nails, and sinuses.
e- Bone marrow transplant recipients are not at risk for invasive aspergillosis.

Answer: D

37- Which statement regarding paracoccidiomycosis is not correct?

a- The etiologic agent is a dimorphic fungus.
b- Most patients acquired their infections in South America.
c- Although the infection is acquired by inhalation and is initiated in the lungs, many patients develop cutaneous and mucocutaneous lesions.
d- The vast majority of patients with active disease are males.
e- The etiologic agent is inherently resistant to amphotericin B.

Answer: E

38- A homeless, malnourished chronic alcoholic presents with severe headache and dyspnea. Physical examination reveals a disheveled man with poor hygiene. His temperature is 41.0 C (105.8 F), blood pressure is 110/78 mm Hg, and pulse is 96/minute and regular. Auscultation of the chest reveals absence of breath sounds over the left middle lung fields. A chest x-ray confirms left lobar pneumonia. Sputum stain reveals partially acid-fast bacilli with branching rods. Which of the following agents is the most likely cause?

a- Mycobacterium avium-intracellulare
b- Mycobacterium kansasii
c- Mycobacterium leprae
d- Mycobacterium tuberculosis
e- Nocardia asteroides

Answer: E

39- A 10-year-old girl with an incomplete vaccination history presents to her pediatrician with a fever of 38.6 C (101.5 F), sore throat, malaise, and difficulty breathing. Physical examination reveals cervical lymphadenopathy and a gray, leathery exudate in the rear of the oropharynx. The area bleeds profusely when disturbed with a tongue depressor. Which of the following correctly describes the causal agent?

a- Gram-negative rod; toxin that inhibits protein synthesis
b- Gram-negative rod; toxin that increases cAMP
c- Gram-positive aerobic rod; toxin that inhibits protein synthesis
d- Gram-positive anaerobic rod; toxin that inhibits protein synthesis
e- Gram-positive aerobic rod; toxin that increases cAMP

Answer: C

40- A 13-year-old girl presents to her pediatrician with fever, malaise, and a sore throat. Physical examination reveals a fever of 39.4 C (103.0 F), cervical lymphadenopathy, and pharyngeal erythema. A swab is taken from some of the tonsillar exudate and cultured on blood agar. Culture reveals beta hemolytic, gram-positive cocci, and a rapid antigen test is positive. What is the major component that protects the causal agent from osmotic damage?

a- Lipopolysaccharide
b- Peptidoglycan
c- Phospholipids
d- Polysaccharide
e- Teichoic acid

Answer: B

Explanation: the causative agent is strep-pyogens (Clues: Beta-hemolysis, gram-positive cocci pharyngitis , tonsillar exudate) , the thick peptidoglycan layers prevents the diffusion of fluid and therefore protects against osmotic damage.

41-A 16-year-old has pneumonia with a dry, hacking cough. The x-ray pattern shows a light, diffuse infiltrative pattern. The most likely organism producing these symptoms is:

a- non-Gram–staining bacterium requiring sterols
b- A bacillus showing granules when stained with methylene blue
c- A bacitracin-sensitive, catalase-negative gram-positive coccus
d- A coagulase positive, gram-positive, catalase positive coccus in clusters
e- A gram-positive bacillus grown on a low oxidation-reduction medium

Answer: A

Explanation: The causative agent is mycoplasma pneumonia (dry hacking cough, diffuse infiltration) which is non-gram stainable requiring sterols for its growth in medium.

42- A 40-year-old homeless man presents to the emergency department with fever and night sweats, coughing up blood. Acid-fast bacilli are identified in his sputum. Which of the following virulence factors allows the causal agent to inhibit phagosome-lysosome fusion to survive intracellularly?

a- Cord factor
b- Calcium dipicolinate
c- Peptidoglycan
d- Sulfatides
e- Tuberculin

Answer: D

43- A 15-day-old boy presents with conjunctivitis. Iodine staining bodies are seen in conjunctival scrapings. The most likely infectious form is a(n):

a- elementary body
b- reticulate body
c- endospore
d- exotoxin
e- vegetative cell

Answer: A

Explanation: The causative agent is chlamydia trichomatis (child , conjunctivitis) the infective form that is able to attach to membrane is the Elementary body only.

44- A 15-year-old girl develops a sore throat, fever, and earache of approximately one week duration. Upon examination by her physician, an erythematous rash is noted covering most of her body and her tongue appears bright red. Which of the following is the description of the causal agent?

a- Gram-positive coccus, alpha hemolytic, catalase negative
b- Gram-positive coccus, beta hemolytic, catalase negative
c- Gram-positive coccus, alpha hemolytic, catalase positive
d- Gram-positive coccus, beta hemolytic, catalase positive
e- Gram-positive coccus, gamma hemolytic, catalase negative

Answer: B

End of microbiology questions

Anatomy-past papers

1- About arytenoid cartilages, all are true except:
a- it has a facet that articulates with the inferior horn of thyroid cartilage
b- pyramidal shape and has 2 surfaces
c- attach to corniculate cartilage at its apex
Answer: A

2- During lower tracheostomy the most vessel liable to injury is :
a - superior thyroid artery
b- inferior thyroid artery
c- inferior thyroid vein
d- internal jugular vein
Answer: C

3- all of the following are present in the bronchopulmonary segment except :
a- segmental bronchus
b- segmental pulmonary vein
c- nerves
d- lymphatics
e- segmental pulmonary artery
Answer: B

4- pseudostratified ciliated columnar epithelium lining all the following except:
a-infraepiglottis
b-vestibular fold
c-conducting bronchiole
d-superior part of nasal cavity (or olfactory part)
Answer: D

5- The lateral wall of the nose:
a- Blood supply comes from branches of both the internal and external carotid artery
b- Innervation through the ophthalmic and maxillary nerves
c- Venous drainage mainly to the cavernous sinus through a large emissary vein

d- Lymphatic drainage through the submandibular lymph nodes and retropharyngeal (upper deep cervical) lymph nodes.
e- All sinuses drain in the middle meatus or infundibulum except the sphenoidal and post ethmoidal sinuses**.**
Answer: C

6- Regarding pterygopalatine fossa; maxillary artery and nerve passing in different directions through

a- pterygomaxillary fissure
b- Infratemporal fossa
c- middle cranial fossa
d- infraorbital canal

Answer: A

7- All of the following nerves supply the lateral wall of the nasal cavity EXCEPT:

a- Anterior ethmoidal nerve
b- Posterior ethmoidal nerve
c- Anterior palatine nerve
d- Posterior superior lateral nasal nerve
e- Anterior superior alveolar

Answer: B

Remember: the anterior palatine nerve is known as the greater palatine nerve.

8- Which of the following structures is least likely to be damaged during the removal of a tumor in the root of the right lung:

a- Phrenic nerve
b- Pulmonary artery
c- Azygous arch
d- Vagus nerve
e- Recurrent laryngeal nerve

Answer: E (the Rt-recurrent isn't related to the thorax).

9- Following a thyroidectomy of a 30-year-old man, the surgeon noticed that he had a weak voice and that the right vocal cord was slack. What possibly could the surgeon have tied together:

a- Internal laryngeal nerve with the superior laryngeal artery
b- Internal laryngeal nerve with the inferior laryngeal artery
c- External laryngeal nerve with the superior thyroid artery
d- Recurrent laryngeal nerve with the inferior thyroid artery
e- Recurrent laryngeal nerve with the inferior laryngeal artery

Answer: C

10-A dentist accidently dropped a tooth and it fell down the respiratory tract. Which of the following is the most possible final destination of the tooth:

a- Left lung, upper lobe, anterior segment
b- Left lung, lower lobe, posterior segment
c- Right lung, middle lobe, medial segment
d- Right lung, lower lobe, apicobasal segment
e- Right lung, lower lobe, posterior segment

Answer: D

11-All the following regarding the pterygopalatine fossa are correct EXCEPT:

a- The maxillary artery enters it through the pterygomaxillary fissure
b- The maxillary nerve enters it through foramen rotundum
c- The parasympathetic ganglia receive preganglionic parasympathetic nerve fibers from the facial nerve
d- The parasympathetic ganglia receive postganglionic sympathetic nerve fibers through the lesser petrosal nerve
e- It communicates with the oral cavity below through the palatine canal

Answer: D

12-All the following regarding the quadrangular membrane are correct EXCEPT:

a- Its upper free margin thickens to form the aryepiglottic folds
b- It's an intrinsic membrane
c- Is innervated by the recurrent laryngeal nerve
d- Its lower free margin thickens to form the false vocal cords
e- Attaches posteriorly to the arytenoid cartilage

Answer: C

13-All the following regarding the maxillary air sinuses are correct EXCEPT:

a- They open into the middle meatus of the nasal cavity
b- Located posteriorly to the pterygopalatine fossa
c- Innervated by branches of the maxillary nerve
d- Extraction of an upper molar tooth can result in formation of a fistula
e- Has a bad drainage especially in chronic sinusitis

Answer: B

14- The muscle that forms part of the true vocal cord is:

a- Thryoarytenoid
b- Cricothryoid
c- Thyrohyoid
d- Transverse arytenoid
e- Oblique arytenoid

Answer: A

15- Which is wrong about arytenoid cartilage:

a- It articulates with other 3 cartilages
b- its mucosa supply by internal laryngeal nerve
c- it gives an attachment to true vocal cords

Answer: A

16-Wrong about pterygopalatine ganglion:

a- it receives preganglionic sympathetic through deep petrosal nerve
b- it located between sphenoid and palatine bones
Answer: A

17-Wrong about bone support lateral nasal wall:

a- ethmoid
b- lacrimal
c- maxilla
d- lateral pterygoid plate of sphenoid
Answer: D

18- Wrong about true vocal cords:

a- has smooth muscle
b- no blood vessels
c- no lymph drainage
d- lined by oral epithelium
Answer: A

19- Wrong about pterygopalatine ganglion:

a- Is parasympathetic and receives preganglionic fibers from the trigeminal Nerve.
b- Receives postganglionic sympathetic from carotid plexus
c- Send pharyngeal nerve through palatovaginal canal to supply glands in the mucosa of nasopharynx
Answer: A

20- All the following have opposing actions except:

a- cricothyroid and thyroarytenoid muscles.
b- Oblique arytenoid and aryepiglotticus muscles.
c- transverse arytenoid and posterior cricoarytenoid muscles
Answer: B

21- Which of the following passes through the opening in thyrohyoid membrane:

a- Inferior laryngeal artery
b- External laryngeal nerve
c- Internal laryngeal nerve
d- Superior thyroid artery
Answer: C

22-The diaphragmatic pleura is supplied by which nerve:

a- Intercostal nerves
b- Phrenic nerve
c- pulmonary plexus

Answer: B

23- Which of the following isn't found in pterygopalatine fossa

a- Maxillary nerve
b- Pterygopalatine ganglia
c- Sphenopalatine nerve
d- First part of the maxillary artery

Answer: D

24- The post ganglionic parasympathetic innervation to lacrimal gland is through:

a- Greater palatine nerve
b- Zygomaticotemporal nerve
c- Long sphenopalatine nerve

Answer: B

25- Which of the following is incorrect about the right pulmonary artery-

a- It originates from pulmonary trunk at sternal angle level
b- It is longer than the left one
c- It is related anteriorly to the SVC and ascending aorta

Answer: A

26- all of the following related left to trachea except: azygous arch

27- Stab in the neck affects: Suprapleural membrane

28-Wrong about cricothyroid muscle: It is innervated by nerve that accompanies superior laryngeal artery (the cricothyroid muscle is innervated by external laryngeal nerve, and the one that accompanies superior laryngeal artery is the internal laryngeal nerve)

29-what is wrong about costodiaphragmatic recess: longest at midclavicular Line (the true is midaxillary line)

30-nerve to pterygoid canal is made of: greater and deep petrosal nerve

31- Wrong: right recurrent laryngeal behind trachea in superior mediastinum

32-stab wound caused pneumothorax can be due to injury through all except:

ninth intercostal space at midclavicular line (the true is midaxillary line)

33-one of the paranasal sinuses is supplied by the superior alveolar nerve:

maxillary air sinus

34- Innervated by recurrent laryngeal nerve and relaxes vocal cords:

Thyroarytenoid

35.wrong about trachea: Posteriorly covered by striated trachealis muscle.

(true is that it is smooth)

36.wrong about nose: The lateral wall is mainly supplied by long

sphenopalatine nerve.

(true is :long sphenopalatine nerve supplies the lower post. Part of nasal septum)

37.not from the branches of third part of maxillary artery:

Buccal artery. (buccal artery branches from 2nd part)

38.correct association between artery and nerve:

Inferior laryngeal artery with recurrent laryngeal nerve.

39.wrong about true vocal cords:

They are thickening of the lower free border of quadrangular membrane

(true is cricovocal membrane)

40.wrong statement: When you insert a canula in pneumothorax , it must be

inserted at the upper border of intercostal space.(true is lower border)

41-Not associated with the lateral wall of nasal cavity: horizontal part of

palatine bone.

42-A patient had a problem with his voice, his doctor found that his left true

vocal cord in the adducted position, what’s true:

his left recurrent laryngeal nerve was ligated with the inferior thyroid artery

during thyroidectomy

43- After thyroidectomy, right vocal cord was found to be paralyzed:

surgeon ligated recurrent laryngeal with inferior thyroid artery

44-Nose bleeding (epistaxis in the Kiesselbach's area) happen because of rupture of: Nasopalatine artery

45-What's wrong about lung carcinoma:
the tumor will cause partial injury to left recurrent laryngeal nerve which will affect the adductors.

46-Not liable to injury when removing a tumor in the hilum: recurrent laryngeal nerve.

47-Wrong about suprapleural membrane: moves upward

48-Which of the following is wrong regarding tracheotomy:
inferior thyroid artery might be injured

49-Which of the following isn't a bony support to the lateral wall of the nose:
medial pterygoid plate of ethmoid bone

50- Impression of what structure is at the left lung medial surface:
Esophagus

51-A patient had pleural effusion & a nurse did aspiration to suck the fluid at the midaxillary line at the upper part of his 9th intercostal space, the second day, he complained of tickling skin sensation that reached the skin of his abdomen (pain sensation from the site of injection to the umbilical region), which is correct:
the needle inserted for aspiration caused injury to his 9th intercostal nerve

52- Wrong: cricoid mucosa innervated by internal laryngeal nerve

53-Wrong about pulmonary arteries: bronchial arteries are branches of them

54-Main artery in Kiesselbach's area: superior labial of facial artery

55-Wrong about pterygopalatine ganglion: parasympathetic postganglionic fibers go to the lacrimal glands through orbital nerves

56-Wrong about suprapleural membrane: attaches to transverse process of first thoracic vertebra (true is C7)

57-Not affected in the dissection of the root of the right lung: recurrent

laryngeal nerve

58-Wrong about the lungs: don't have lymph nodes

59-Wrong about sphenoid air sinus: drains into superior meatus

60-No symmetry in the superficial anatomy of the lungs in: the anterior

border below sternal angle

61-Wrong about conus elasticus: innervated by internal laryngeal nerve

62-Leaves pterygopalatine fossa to the infratemporal fossa: maxillary nerve

63-What nerve supplies cricothyroid muscle: external laryngeal nerve

64-A nerve to the left of the trachea with a recurrent nerve: vagus nerve

65- Greater palatine artery is a branch of

a- Maxillary artery in pterygopalatine fossa
b- Facial artery
c- Maxillary artery in lateral nasal wall
d- Anterior ethmoidal artery

Answer: A

66- After suffering from sinusitis, an oral fistula is formed with:

a- Maxillary sinuses
b- Frontal sinuses
c- Ethmoidal sinuses
d- Sphenoidal sinuses

Answer: A

67- All of the following are lined with by pseudostratified columnar epithelium with goblet cells except :

a- Olfactory region
b- Terminal bronchioles
c- Posterior surface of epiglottis
d- False vocal cord

Answer: B

68- needle in the left ninth intercostal space at mid-axillary line wouldn't affect

a- Diaphragm
b- Spleen
c- Lung
d- Pleura

e. Peritoneum

Answer: C

69-Which of these muscles causes closure of Rima glottidis in case of recurrent laryngeal nerve injury:

a- Lateral crico-arytenoid muscle
b- Transverse arytenoid muscle
c- Posterior cricoarytenoid muscle
d- Vocalis muscle
Answer: C

End of anatomy questions

Histology and embryology-past papers

1-Type II alveolar cells are associated with all of the following EXCEPT:

a- They form 16% of the interalveolar septum
b- They form 8% of the alveolar wall
c- They contain in their cytoplasm lamellar bodies
d- They have the ability to regenerate their own type as well as type I cells
e- They are connected to type I alveolar cells by occluding junctions and desmosomes
Answer: B

2-The laryngotracheal groove is formed during:

a- 2nd week of pregnancy
b- 4th week of pregnancy
c- 6th week of pregnancy
d- 5th week of pregnancy
e- 7th week of pregnancy
Answer: B

3-All of the following cells are located in the olfactory region of the nose

EXCEPT:

a- Pseudostratified ciliated columnar epithelium
b- Sustentacular cells
c- Olfactory cells
d- Bowman's gland
e- Goblet cells
Answer: E

4- Which of the following conditions are associated with oligohydramnios:

a- Laryngeal atresia
b- Tracheoesophageal fistula
c- Congenital cyst of the lung
d- Ectopic lung lobe
e- Pulmonary hypoplasia
Answer: E

5- An x-ray was done to a child one day after birth. The x-ray showed peripheral opaque areas in the lung. What is the most common cause of such a condition?

a- Collapsed lung due to traumatic delivery
b- Congenital absence of surfactant
c- Congenital absence of the alveoli
d- Obstruction of the distal airways
e- This is a normal condition, where the alveoli will inflate several days after delivery
Answer: E

6-All of the following are present in the olfactory region EXCEPT:

a- Bipolar cells
b- Bowman serous gland
c- Von Ebner gland + seromucous secretion.
d- Basal cells
Answer: C

7- psuedostrtified ciliated columnar epithelium lining all of the following except:

a- infraepiglottis
b- vestibular fold
c- conducting bronchiole
d- superior part of nasal cavity (or olfactory part)
e- nasopharynx
Answer: C

8-the development of the tracheoesophageal septum occurs at week:

a- 2
b- 3
c- 4
d- 5
e- 6
Answer: C

9-which is not present in the blood-air barrier?

a- cytoplasm of endothelial cells
b- cytoplasm of alveolar cells
c- fused basal lamina
d- surfactant
e-thickness of 0.1 - 1.5 millimeter

Answer: E

10-All the following is lined by Pseudostratified columnar epithelium with goblet cells except?

a- Olfactory region
b- End of terminal bronchiole
c- posterior surface of epiglottis
d- False vocal cord
Answer: B

11-Which of the following is not found in the respiratory membrane?

a- Surfactant layer
b- Type II pneumocyte
c- Type 1 pneumocyte
d- Endothelial cell
e- Fused basal lamina
Answer: B

12-Oligohydramnios is associated with?

a- Ectopic lung lobes
b- Lung hypoplasia
c- Lung agenesis
d- ARDS
Answer: B

13- Wrong about ARDS

a- Thyroxine is the most important stimulator
b- Causes collapsing of the alveoli
c- Accounts for 2% of death in neonates
Answer: C

14- Functionally the important microscopic anatomy of the lung consist of what is called a respiratory membrane, which consist of?

a- The epithelium of the alveolus
b- an alveolar basement membrane
c- A capillary basement membrane
d- the Endothelium of the capillary

e- all the above
Answer: E

15- A premature baby usually has difficulty breathing, However the respiratory system developed enough for survival by:

a- 17 weeks
b- 24 weeks
c- 28 week
d- 36 weeks
e- none of the above
Answer: C

16- Most Inspired particles such as dust fail to reach the Lung because of

the:

a- Ciliated mucous lining in the nose
b- porus structure of the nasal conchae
c- Abundant blood supply to nasal mucosa
d- Action of the epiglottis
e- None of the above
Answer: A

17- Which of the following is false regarding secondary bronchi?

a- They have complete muscular layer

b- Cartilage plates gradually disappear

c- Goblet cells are rarely seen
Answer: C

18- Region that has columner epithelium with muscle but without cartilage:

bronchioles

19- The appearance of the laryngeotracheal groove is in: 4th week

20- The lack of the development of cartilage in the bronchus causes:

bronchial stenosis

21- Wrong about terminal sac period of lung maturation: lack of respiratory

membrane

22- Wrong about Type II cells: have proteolytic enzyme granules

23- Baby vomits what eats: tracheoesophageal fistula

24- Wrong about Lung: Type I alveolar cells are most abundant

25- Most numerous cells in the lungs: dust cells

26- Wrong about surfactant: Usually deficient in “term” babies

27- wrong: the growth of alveoli after birth is mainly by increase in size

28- wrong about tracheoesophageal fistula or atresia: it causes pulmonary hypoplasia

29- wrong about clara cells: they exist rarely in the respiratory bronchioles

30- lung opacity in new born: Its normal

31- Wrong about terminal bronchioles: have few glands in the lamina Propria.

32- what is wrong about dust cell/macrophages: present in respiratory membrane

33- cleft lip results from failure of fusion of: Maxillary prominences and nasal medial.

34- baby suffers from vomiting and regurgitation upon feeding: Esophageal atresia and trachea-esophageal fistula.

35- wrong about trachea: Posteriorly covered by striated trachealis muscle.

36- wrong about clara cells: Is part of diffuse neuro-endothelial system.

37- C-shaped trachea cartilage is derived from: Splanchnic mesoderm

38- wrong about clara cells: They aren’t present in terminal bronchioles.

39- an infant with polyhydraminous that was born with a lot of amniotic fluid in his mouth, which of the following is mostly the cause: proximal esoghegial atresia with tracheoesophageal fistula.

End of histology-embryology questions

Pathology-questions

1- A 7-year-old boy accidentally inhales a small peanut, which lodges in one of his bronchi. A chest x-ray reveals the mediastinum to be shifted toward the side of the obstruction. The best description for the lung changes that result from this obstruction is:
a- Absorptive atelectasis
b- Compression atelectasis
c- Contraction atelectasis
d- Patchy atelectasis
e- Hyaline membrane disease
Answer: A

2- Histologic sections of lung tissue from an individual with adult respiratory distress syndrome (ARDS) are most likely to reveal:
a- Angio invasive infiltrates of pleomorphic lymphoid cells
b- Deposits of needle-like crystals from the membranes of eosinophils
c- Infiltrating groups of malignant cells having intercellular bridges
d- Irregular membranes composed of edema, fibrin, and dead cells lining alveoli
e- Plexiform lesions within pulmonary arterioles
Answer: D

3- A 19-year-old female presents with urticaria that developed after she took aspirin for a headache. She has a history of chronic rhinitis, and physical examination reveals the presence of nasal polyps. This patient is at an increased risk of developing which one of the following pulmonary diseases following the ingestion of aspirin?
a- Asthma
b- Chronic bronchitis
c- Emphysema
d- Interstitial fibrosis
e- Pulmonary hypertension
Answer: A

4- Which one of the following is a correct association concerning the pathogenesis of smoking-induced emphysema?
a- Destruction of distal acinus = centrilobular emphysema
b- Destruction of distal acinus = paraseptal emphysema
c- Destruction of entire acinus = panlobular emphysema
d- Destruction of proximal acinus = centrilobular emphysema
e- Destruction of proximal acinus = paraseptal emphysema
Answer: D

5- An abnormality that inhibits the normal functioning of the ATPase containing dynein arms of cilia is most likely to produce:
a- Asthma
b- Bronchiectasis
c- Cirrhosis
d- Emphysema
e- Steatosis
Answer: B

6- A 24-year-old African American female presents with nonspecific symptoms including fever and malaise. A chest x-ray reveals enlarged hilar lymph nodes ("potato nodes"), while her serum calcium level is found to be elevated. Biopsies of the enlarged hilar lymph nodes would most likely reveal:
a- Caseating granulomas
b- Dense, granular, PAS-positive, eosinophilic material
c- Markedly enlarged epithelial cells with intranuclear inclusions
d- Noncaseating granulomas
e- Numerous neutrophils with fibrin deposition
Answer: D

7- Which ONE of the following is not a histological feature of chronic bronchitis?
a- Calcification of bronchial cartilages.
b- Goblet cell metaplasia.
c- Hypertrophy of smooth muscle.
d- Mucous gland hyperplasia
e- Squamous metaplasia of respiratory epithelium.
Answer: C

8- A 26-year-old woman with postpartum sepsis is afebrile on antibiotic therapy, but she has had worsening oxygenation over the past 3 days. Her chest radiograph shows scattered bilateral pulmonary opacifications. A ventilation-perfusion scan shows areas of mismatch. Which of the following microscopic findings is most likely to be present in her lungs?
a- Alveolar hyaline membranes
b- Arterial plexiform lesions
c- Interstitial fibrosis
d- Lymphocytic infiltrates
e- Respiratory bronchiolar destruction
Answer: A

9- After a hemicolectomy to remove a colon carcinoma, a 56-year-old man develops respiratory distress. He is intubated and receives mechanical ventilation with 100% oxygen. Three days later, his arterial oxygen saturation decreases to 60%. A chest radiograph shows increasing opacification in all lung fields. A transbronchial lung biopsy specimen on microscopic examination shows hyaline membranes lining distended alveolar ducts and sacs. Which of the following is the most likely mechanism underlying these morphologic changes?

a- Aspiration of oropharyngeal contents
b- Intravascular thrombi with coagulopathy
c- Leukocyte-mediated injury to alveolar capillaries
d- Reduced production of surfactant
e- Release of fibro genic cytokines by macrophages

Answer: C

10-A 20-year-old, previously healthy man is jogging one morning when he trips and falls to the ground. He suddenly becomes markedly short of breath. On examination in the emergency room there are no breath sounds audible over the right side of the chest. A chest radiograph shows shift of the mediastinum from right to left. A chest tube is inserted on the right side, and air rushes out. Which of the following underlying diseases is most likely to have produced this complication?

a- Asthma
b- Bronchiectasis
c- Centriacinar emphysema
d- Chronic bronchitis
e- Distal acinar emphysema
f- Panlobular emphysema

Answer: E

11-A 49-year-old man has had increasing dyspnea for the past 4 years. He has an occasional cough with minimal sputum production. On physical examination, his lungs are hyperresonant with expiratory wheezes. Pulmonary function tests show increased total lung capacity (TLC) with slightly increased FVC and decreased FEV1 and FEV1/FVC ratio. Arterial blood gas measurement shows pH of 7.35; Po2, 65 mm Hg; and Pco2, 50 mm Hg. Which of the following disease processes should most often be suspected as a cause of these findings?

a- Centrilobular emphysema
b- Chronic pulmonary embolism
c- Diffuse alveolar damage
d- Nonatopic asthma
e- Sarcoidosis
f- Silicosis

Answer: A

12- A 33-year-old man has had increasing dyspnea for the past 8 years. He does not smoke. On examination, there are decreased breath sounds over lower lung fields. A chest radiograph shows flattened diaphragms; his CT scan is shown in the figure. Pulmonary function tests show decreased DLCO, decreased FEV1, and increased FVC. Arterial blood gas analysis shows Po2, 65 mm Hg; Pco2, 60 mm Hg; HCO3 –, 32 mEq/L; and pH, 7.35. A sibling is similarly affected. What is the most likely mechanism for his pulmonary disease?

a- Atopy with IgE binding to mast cells
b- CFTR gene mutation
c- Increased neutrophil proteases
d- Prior infection with tuberculosis
e- Reduced antielastase activity
Answer: E

13- A 45-year-old man has smoked two packs of cigarettes per day for 20 years. For the past 4 years, he has had a chronic cough with copious mucoid expectoration. During the past year, he has had multiple respiratory tract infections diagnosed as “viral flu.” He has also developed difficulty breathing, tightness of the chest, and audible wheezing. His breathing difficulty is relieved by inhalation of a β-adrenergic agonist and disappears after the chest infection has resolved. Which of the following pathologic conditions is most likely responsible for his clinical condition?

a- α1-Antitrypsin deficiency with panlobular emphysema
b- Centrilobular emphysema with cor pulmonale
c- Chronic asthmatic bronchitis
d- Cystic fibrosis with bronchiectasis
e- Hypersensitivity pneumonitis with restrictive lung disease
Answer: C

14- A study is conducted of individuals who smoked at least one pack of cigarettes per day for 30 years. These individuals undergo pulmonary function testing, and a large subset is found to have decreased FEV1, normal to decreased FVC, and FEV1/FVC ratios less than 70%. Autopsy data from this subset of individuals in the study with a low FEV1/FVC ratio are analyzed. Which of the following respiratory tract structures in the lungs is likely to be affected most by the underlying disease?

a- Alveolar duct
b- Alveolar sac
c- Bronchi
d- Respiratory bronchiole
e- Terminal bronchiole
Answer: D

Explanation: FEV1/FVC ratio is decreased is indicative of obstructive lung disease particularly emphysema , Smoking is strongly associated with Centri-acinar emphysema hence D

15- A 62-year-old man is a smoker with a 10-year history of cough productive of copious mucopurulent sputum. Over the past 6 months, he has developed progressive dyspnea. Physical examination shows bilateral pedal edema and a soft but enlarged liver. A chest radiograph shows bilateral pleural effusions and a prominent right heart border. Arterial blood gas values are Po2, 60 mm Hg; Pco2, 52 mm Hg; pH, 7.30; and HCO3−, 29 mEq/L. He is intubated and placed on a ventilator, and he requires increasing amounts of oxygen. Which of the following microscopic findings is most likely to be present in the affected lungs?

a- Bronchovascular distribution of granulomas
b- Carcinoma filling lymphatic spaces
c- Extensive interstitial fibrosis
d- Hypertrophy of bronchial submucosal glands
e- Mucosal infiltrates of eosinophils

Answer: D

Explanation: This patient has chronic bronchitis, which is characterized by D, hints: productive cough, smoking history, bilateral pleural effusions indicative of heart failure

16- A 12-year-old girl has a 7-year history of coughing and wheezing and repeated attacks of difficulty breathing. The attacks are particularly common in the spring. During an episode of acute respiratory difficulty, a physical examination shows that she is afebrile. Her lungs are hyperresonant on percussion, and a chest radiograph shows increased lucency of all lung fields. Laboratory tests show an elevated serum IgE level and peripheral blood eosinophilia. A sputum sample examined microscopically also has increased numbers of eosinophils. Which of the following histologic features is most likely to characterize the lung in her condition?

a- Dilation of respiratory bronchioles with loss of elastic fibers
b- Inflammatory destruction of bronchial walls
c- Interstitial and alveolar edema with hyaline membrane formation
d- Patchy areas of consolidation with leukocytic exudates in alveoli
e- Remodeling of airways with smooth muscle hyperplasia

Answer: E

17- A 36-year-old woman has had a low-grade fever and worsening nonproductive cough and dyspnea for the past 2 years. On examination, she has breath sounds in all lung fields. A chest CT scan shows the findings in the figure. An arterial blood gas shows pH, 7.45; Po2, 83 mm Hg; Pco2, 30 mm Hg; and HCO3 –, 19 mEq/L. Pulmonary function tests show total lung capacity 3 L (60% of predicted), FEV1 2.5 (66% of predicted), and DLCO 10 mL/min/mm Hg (50% of predicted). Her pulmonary compliance is reduced. What is the most likely diagnosis?

a- α1-Antitrypsin deficiency
b- Chronic bronchitis
c- Diffuse alveolar damage
d- Nonatopic asthma
e- Sarcoidosis

Answer: E

End of pathology questions. **AQ**